

Thomas M. Donnelly, DVM, Column Editor

What's your diagnosis?

Pruritus and Alopecia in Guinea Pigs

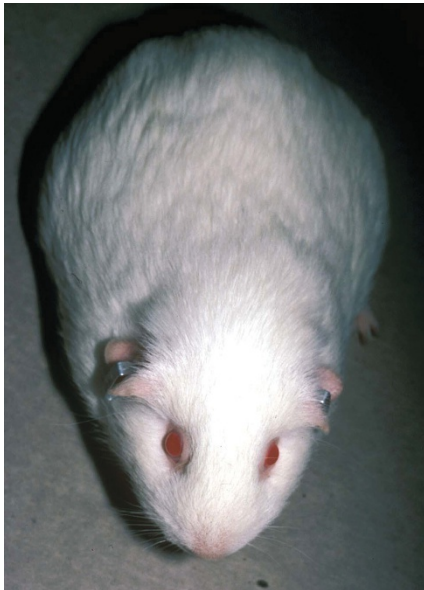


FIGURE 1. A guinea pig with mild scratching around the head and shoulders. Clinically the animal looks unremarkable except for showing pruritus.

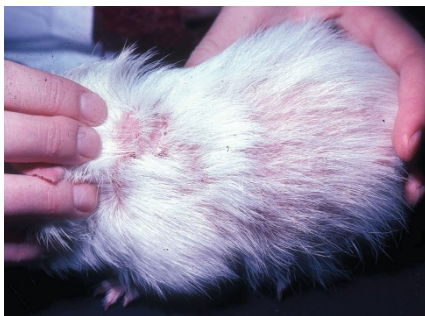


FIGURE 2. A guinea pig with moderate to severe scratching around head, shoulders, and dorsum. There is moderate patchy alopecia and mild seborrhea.

A colony of guinea pigs at a regional university in New South Wales, Australia had a history of alopecia and pruritus for several months. Animal care technicians first noticed the pruritus in young guinea pigs. Animals would scratch around the head and shoulders, but with time the scratching spread to all of the body. Fur would come out initially over the shoulders and patchy alopecia would develop (Figs. 1 and 2). In some animals, the alopecia was widespread and skin sores developed from self-trauma (Figs. 3 and 4).

Since first noticed, most guinea pigs in the colony of approximately 50 animals became pruritic. In the last month, the scratching had become severe, and some young animals had suffered from seizures. These animals were euthanized.

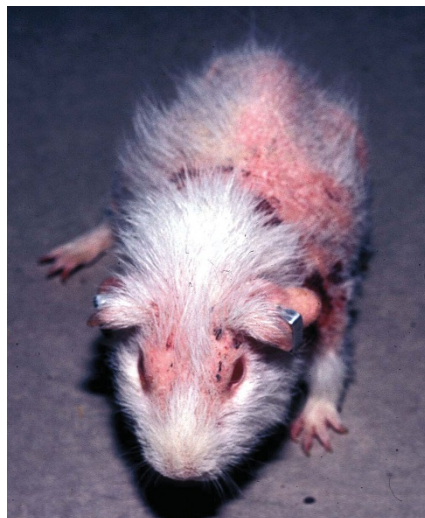


FIGURE 3. A young guinea pig with severe scratching over all the body. The animal is almost bald from hair loss and there are self-inflicted skin lesions on the head and shoulders.

The animals were housed on pine-chip bedding, fed a commercial guinea pig diet, and given fresh leafy vegetables and lucerne (alfalfa) hay to supplement their diet. Animal care technicians provided fresh water daily in water bottles with lick-ers.

On examination of the colony, severely affected guinea pigs showed intense pruritus, widespread alopecia, and greasy skin with self-inflicted sores. Based on the history and clinical signs, what do you think is the cause of the pruritus and alopecia? How would you confirm it? What are your recommendations for treatment?

What's your diagnosis?

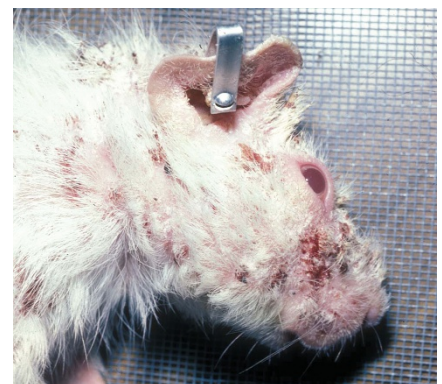

FIGURE 4. The head and shoulders of a dead guinea pig that animal technicians euthanized due to severe pruritus and seizures. Notice the self-inflicted skin sores from scratching on and around the head.