

Conflict of interest

The authors declare no conflict of interest.

References

- 1 Kohlhaas M, Spoerl E, Schilde T, Unger G, Wittig C, Pillunat LE. Biomechanical evidence of the distribution of cross-links in corneas treated with riboflavin and ultraviolet a light. *J Cataract Refract Surg* 2006; **32**: 279–283.
- 2 Wollensak G, Spoerl E, Seiler T. Riboflavin/ultraviolet-a-induced collagen crosslinking for the treatment of keratoconus. *Am J Ophthalmol* 2003; **135**: 620–627.
- 3 Wollensak G. Crosslinking treatment of progressive keratoconus: new hope. *Curr Opin Ophthalmol* 2006; **17**: 356–360.
- 4 Tu KL, Aslanides IM. Orbscan II anterior elevation changes following corneal collagen cross-linking treatment for keratoconus. *J Refract Surg* 2009; **25**: 715–722.
- 5 Malhotra C, Shetty R, Kumar RS, Veluri H, Nagaraj H, Shetty KB. In vivo imaging of riboflavin penetration during collagen cross-linking with hand-held spectral domain optical coherence tomography. *J Refract Surg* **28**: 776–780.
- 6 Spoerl E, Mrochen M, Sliney D, Trokel S, Seiler T. Safety of UVA-riboflavin cross-linking of the cornea. *Cornea* 2007; **26**: 385–389.
- 7 Kanellopoulos AJ. Collagen cross-linking in early keratoconus with riboflavin in a Femtosecond laser-created pocket: initial clinical results. *J Refract Surg* 2009; **25**: 1034–1037; 86.

M Balidis^{1,2}, VE Konidaris², G Ioannidis^{1,3}
and AJ Kanellopoulos^{4,5}

¹Ophthalmica Eye Institute, Thessaloniki, Greece
²AHEPA University Hospital, Thessaloniki, Greece
³Ippocraton General Hospital, Thessaloniki, Greece
⁴New York University Medical College and Manhattan Eye, Ear and Throat Hospital, New York, NY, USA
⁵Laservision.gr Institute, Athens, Greece
 E-mail: balidis@perfectvision.gr

Eye (2014) **28**, 1258–1260 doi:10.1038/eye.2014.155;
 published online 25 July 2014

**Sir,
 Perfluoropropane (C₃F₈) gas injection followed by deep anterior lamellar keratoplasty (DALK) in severe keratoconus**

Acute corneal hydrops is the rapid development of corneal edema due to tears in the Descemet’s membrane. Perfluoropropane gas (C₃F₈) injection has been found useful in early resolution of hydrops.¹ Although gas injection has been found to accelerate the recovery of corneal hydrops, hydrops resolves spontaneously in most cases and reports of accelerated recovery do not refer to any control group. We present a case of hydrops in severe keratoconus managed by C₃F₈ injection and

visually rehabilitated by deep anterior lamellar keratoplasty (DALK).

Case report

A 19-year-old male presented in December 2012 with corneal hydrops of 3 weeks duration in his left eye. The Descemet’s tear was central and localized. Non-expansile 14% C₃F₈ gas was injected in the operating room. Three weeks following injection, edema totally resolved (Figure 1). OCT showed extensive thinning of the entire cornea (Figure 2).

On 31 March 2013, DALK was performed. Partial thickness trephination was done with 9 mm trephine, which was decentered inferiorly to include the cone. Lamellar dissection was done manually without injection of air into the corneal stroma. Donor graft (9.5 mm) was sutured to the bed after removing the DM.

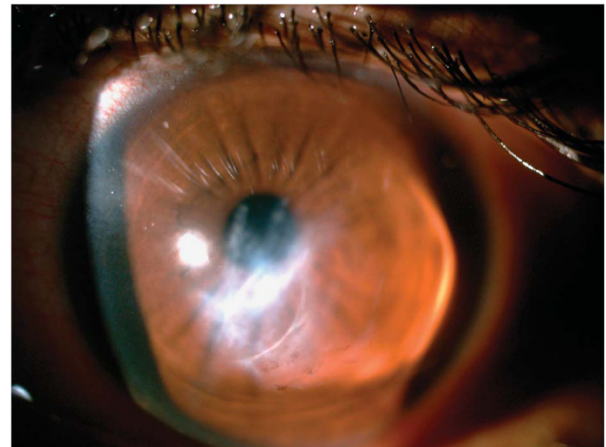


Figure 1 Diffuse slit-lamp view showing resolved hydrops following C₃F₈ injection.

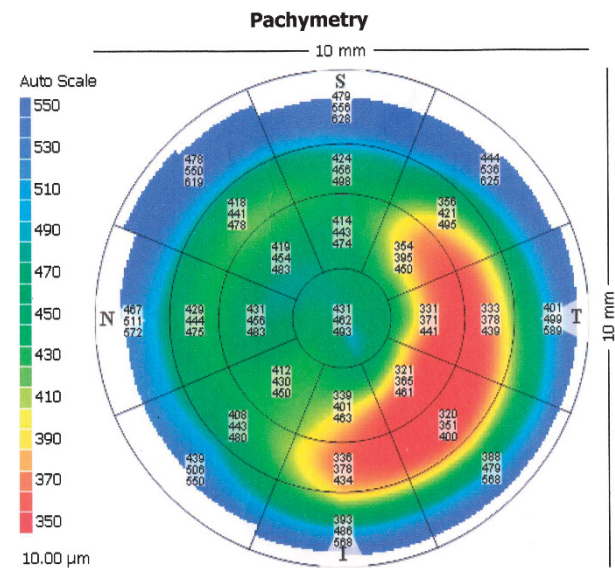


Figure 2 OCT image after resolution of hydrops.

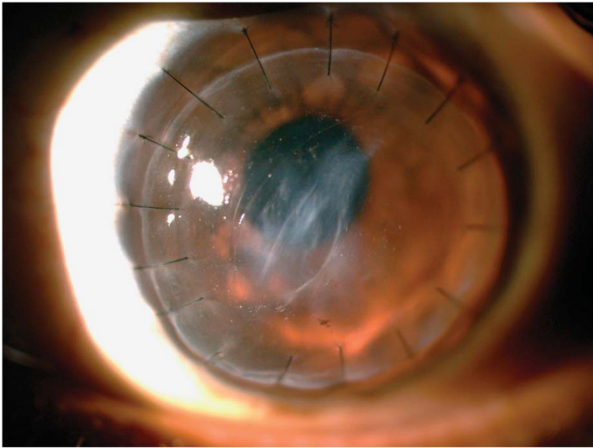


Figure 3 Diffuse slit-lamp view of the same eye following DALK with Descemet's membrane scar.

Following surgery, the patient had a visual acuity of 20/80 with a correction of $-4.5\text{ D}/-1.5\text{ D Cyl @}70$ degrees. Descemet's scar was visible (Figure 3).

Comment

Intracameral C_3F_8 gas is a useful modality for fast resolution of corneal edema in acute corneal hydrops in keratoconus.² Although clinically early resolution of edema has been noted in case reports and series, complications of glaucoma and fixed dilated pupil in acute corneal hydrops or following DALK have been reported.^{3–5} A case report of non-resolution of acute hydrops because of intrastromal migration of C_3F_8 gas has been reported.⁶ Hence, careful follow-up of intraocular pressure and gas status is mandatory after C_3F_8 gas injection.

We decided to do DALK in the case reported, as the thinning was extensive and was reaching the limbus. Zhang *et al*⁷ reported satisfactory visual outcomes with both PK and DALK in treating keratoconus.

To conclude, we present a case of hydrops managed by C_3F_8 injection followed by DALK.

Conflict of interest

The authors declare no conflict of interest.

References

- Shah SG, Sridhar MS, Sangwan VS. Acute corneal hydrops treated by intracameral injection of perfluoropropane (C_3F_8) gas. *Am J Ophthalmol* 2005; **139**: 368–370.
- Basu S, Vaddavalli PK, Ramappa M, Shah S, Murthy SI, Sangwan VS. Intracameral perfluoropropane gas in the treatment of acute corneal hydrops. *Ophthalmology* 2011; **118**: 934–939.
- Vanathi M, Mohan S, Dada T, Panda A. Malignant glaucoma after intracameral isoexpansile perfluoropropane tamponade for the management of acute corneal hydrops. *Cornea* 2010; **29**(7): 838–839.

- Maurino V, Allan BD, Stevens JD, Tuft SJ. Fixed dilated pupil (Urrets-Zavalía syndrome) after air/gas injection after deep lamellar keratoplasty for keratoconus. *Am J Ophthalmol* 2002; **133**(2): 266–268.
- Aralikatti AK, Tomlins PJ, Shah S. Urrets-Zavalía syndrome following intracameral C_3F_8 injection for acute corneal hydrops. *Clin Experiment Ophthalmol* 2008; **36**(2): 198–199.
- Sharma N, Mannan R, Titiyal JS. Nonresolution of acute hydrops because of intrastromal migration of perfluoropropane gas. *Cornea* 2010; **29**(8): 944–946.
- Zhang YM, Wu SQ, Yao YF. Long-term comparison of full-bed deep anterior lamellar keratoplasty and penetrating keratoplasty in treating keratoconus and penetrating keratoplasty in treating keratoconus. *J Zhejiang Univ Sci B* 2013; **14**: 438–450.

N Narayan and MS Sridhar

Maxivision Eye Hospital & Laser Centre, Hyderabad, India

E-mail: drniteshnarayan@gmail.com

Eye (2014) **28**, 1260–1261; doi:10.1038/eye.2014.159;

published online 18 July 2014

Sir, Trendelenburg positioning with temporal approach for vitreoretinal surgery in a patient with severe kyphosis

While vitrectomy is typically performed with the patient supine, technical difficulties arise in patients who are unable to lie flat. Modified equipment and patient positioning have been described for cataract surgery.^{1,2} However, no position modifications have been described for vitreoretinal surgery. We report a positioning and surgical technique for pars plana vitrectomy in a severely kyphotic patient.

Case report

A 65-year-old male with severe kyphosis and prior cervical vertebral fusion with limited neck extension presented with retained lens fragments after cataract surgery and medically uncontrolled intraocular pressure in the left eye. Ability to position supine was tested in an examination chair (Figures 1a and b). Intra-operatively, the gurney was tilted to a Trendelenburg position ($25\text{--}45^\circ$, head down). The patient's neck and shoulders were supported with foam pillows and towels that were taped, and the patient's thighs were supported by pillows. The surgical belt was tightened. A stool was placed under the head of the bed for support, in the event of bed breakage from extreme positioning (Figure 1c). The operating microscope with wide-angle viewing system (OPMI LUMERA 700 and RESIGHT, Carl Zeiss Meditec, Jena, Germany) was rotated 20° to align with the corneal plane. A temporal surgical approach was used (Figure 1d). Intraocular pressures were 20.5 mm Hg in the right eye and 19.5 mm Hg in the left eye, measured by a pneumatonometer. A mild intravenous anesthetic was administered, followed by sub-Tenon's anesthesia. Three-port