

## References

- 1 Georg LK, Brown JM. *Rothia*, General nov., an aerobic genus of the family Actinomycetaceae. *Int J Syst Bacteriol* 1967; **17**: 79–88.
- 2 Ferraz V, McCarthy K, Smith D, Koornhof HJ. *Rothia dentocariosa* endocarditis and aortic root abscess. *J Infect* 1998; **37**: 292–295.
- 3 Boudewijnss M, Magerman K, Verhaegen J, Debrock G, Peetermans WE, Donkersloot P *et al.* *Rothia dentocariosa*, endocarditis and mycotic aneurysms: case report and review of the literature. *Clin Microbiol Infect* 2003; **9**: 222–229.
- 4 Llopis F, Carratala J. Vertebral osteomyelitis complicating *Rothia dentocariosa* endocarditis. *Eur J Clin Microbiol Infect Dis* 2000; **19**: 562–563.
- 5 Shin JH, Shim LD, Kim HR, Sinn JB, Kook JK, Lee JN. *Rothia dentocariosa* septicaemia without endocarditis in a neonatal infant with meconium aspiration syndrome. *J Clin Microbiol* 2004; **42**: 4891–4892.
- 6 Schiff MJ, Kaplan MH. *Rothia dentocariosa* pneumonia in a immunocompromised patient. *Lung* 1987; **165**: 279–282.
- 7 Bibashi E, Kokolina E, Mitsopoulos E, Kontopoulou K, Sofianou D. Peritonitis due to *Rothia dentocariosa* in a patient receiving continuous ambulatory peritoneal dialysis. *Clin Infect Dis* 1999; **28**: 696.
- 8 Mackinnon MM, Amezcaga MR, MacKinnon JR. A case of *Rothia dentocariosa* endophthalmitis. *Eur J Clin Microbiol Infect Dis* 2001; **20**: 756–757.

AM Partner<sup>1</sup>, S Bhattacharya<sup>2</sup>, RAH Scott<sup>1</sup> and P Stavrou<sup>1</sup>

<sup>1</sup>Birmingham and Midland Eye Centre, Sandwell and West Birmingham NHS Trust, Birmingham, UK

<sup>2</sup>Microbiology Department, Sandwell and West Birmingham NHS Trust, Birmingham, UK

Correspondence: P Stavrou, Birmingham and Midland Eye Centre, Sandwell and West Birmingham NHS Trust, Birmingham B18 7QU, United Kingdom

Tel: +44 121 5076854;

Fax: +44 121 5076853.

E-mail: panagiotastavrou@hotmail.com

*Eye* (2006) **20**, 502–503. doi:10.1038/sj.eye.6701902; published online 29 April 2005

Sir,

### Central serous chorioretinopathy associated with testosterone therapy

Central serous chorioretinopathy (CSR) is characterised by serous elevation of neurosensory retina at the posterior pole. It typically affects young and middle aged

men. Type A personality, male gender, emotional stress, pregnancy, increased levels of endogenous cortisol<sup>1</sup> and treatment with corticosteroids<sup>2</sup> have been associated with central serous chorioretinopathy. We report a case of CSR in a patient on regular testosterone therapy because of hypogonadotropic hypogonadism.

### Case report

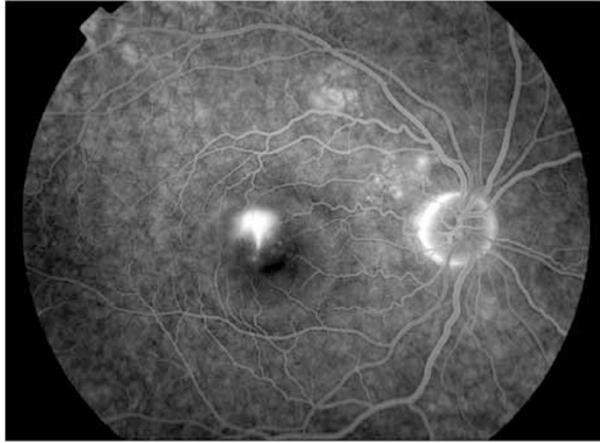
A 52-year-old man presented to eye clinic with a 1-week history of grey patch in front of his right eye. He never had any significant ocular problem in the past. He was diagnosed with acromegaly 24 years ago and subsequently had trans-sphenoidal surgery 7 years later, and radiotherapy 13 years later. Four years ago, he developed hypogonadotropic hypogonadism and he was started on testosterone replacement regime of injection testosterone 500 mg every four weekly. At 1 month prior to his presentation, testosterone dose was increased to 500 mg every three weekly as he was losing early morning erection. At 2 weeks before presentation, his serum hormone profile was carried out, which showed peak testosterone levels of more than 69 mmol/l (normal: 10–35 mmol/l). The serum cortisol levels and growth hormone levels were normal. He was not taking any other medication although he had been on bromocriptine in the past.

On examination his visual acuity in right eye was 6/18 and 6/6 in left eye. The anterior segment examination of both eyes was unremarkable. Dilated fundus examination of the right eye with slit-lamp biomicroscopy showed neurosensory serous detachment of about 2-disc diameter centred at fovea. These findings were consistent with central serous chorioretinopathy. The patient underwent fundus fluorescein angiography to rule out choroidal neovascular membrane, which revealed typical CSR (Figure 1). At 4 week follow-up appointment his visual symptoms were slightly better, and dilated fundus examination of right eye showed resolving CSR. At this stage, his blood peak testosterone levels were 34 mmol/l. In 6 weeks time his central serous retinopathy resolved completely with no sequels. The testosterone trough levels at this stage were normal at 14.9 mmol/l and so were the growth hormone and cortisol levels.

After 6 months, his visual acuity remained 6/6 with no ocular symptoms. He was still on 500 mg testosterone injection every third week and his hormone levels were in normal range.

### Comments

Central serous chorioretinopathy typically affects males from 20 to 45 years old, however, there are case reports of CSR occurring in patients of 60 years or older.<sup>3</sup> The



**Figure 1** Late frame of fundus fluorescein angiogram of right eye showing typical CSR.

aetiology and pathogenesis of CSR remain obscure although several hypothesis have been advanced. These include abnormal choroidal vascular hyperpermeability, physical defect in Bruch's membrane and localised retinal pigment epithelium (RPE) dysfunction. Corticosteroids have long been implicated in the pathogenesis of CSR. Gass and Little<sup>4</sup> postulated that a major breakdown occurs in the permeability of the choriocapillaris, thus enabling large protein molecules and fluid to enter into subretinal space. By inhibiting fibroblastic proliferation and enhancing capillary fragility, corticosteroids are assumed to impair the eye ability to repair the focal damage to choriocapillaris. Corticosteroids also interfere with ion transport across RPE according to this hypothesis. Glucocorticoids also cause structural alteration of the Bruch's membrane by inhibiting collagen synthesis.<sup>1</sup> Further evidence comes from the fact that elevated plasma cortisol levels are found during normal pregnancy<sup>5</sup> and in patients with type A personality,<sup>6</sup> conditions that are associated with CSR.

Androgens or testosterone have never been implicated as a factor involved in the pathogenesis of CSR, however, there is clinical and experimental evidence that associates testosterone with CSR. The fact that incidence of CSR is much higher in males as compared to females and it decreases as the age advances correlates with the levels of plasma testosterone. There is a gradual decline in total plasma testosterone levels with advancing age in older men.<sup>7</sup> Furthermore, plasma testosterone levels are higher in people with type A behaviour<sup>8</sup> and in normal pregnancy.<sup>9</sup> Testosterone is known to promote atherosclerosis, retain sodium and experimental studies have shown that it affects the vascular tone. Human RPE cells are found to have androgen receptors.<sup>10</sup>

Intramuscular testosterone therapy is known to cause fluctuation of plasma testosterone levels. Our patient developed an acute rise of plasma testosterone levels after his testosterone dose was increased, which was followed by the development of CSR. The temporal relation of serum testosterone levels and development of CSR in this case shows an association between the two, which needs to be further investigated.

In summary, this is a first reported case of central serous chorioretinopathy associated with systemic testosterone therapy.

## References

- 1 Bouzas EA, Scott MH, Mastorakos S, Chrousos GP, Kaiser-Kupfer MI. Central serous chorioretinopathy in endogenous hypercortisolism. *Arch Ophthalmol* 1993; **111**(9): 1229–1233.
- 2 Spraul CW, Lang GE, Lang GK. Retinal pigment epithelial changes associated with systemic corticosteroid treatment. Report of cases and review of literature. *Ophthalmologica* 1998; **212**(2): 142–148.
- 3 Schatz H, Madeira D, Johnson RN, McDonald HR. Central serous chorioretinopathy occurring in patients 60 years of age or older. *Ophthalmology* 1992; **99**(1): 63–67.
- 4 Gass JDM, Little H. Bilateral bullous exudative retinal detachment complicating idiopathic central serous chorioretinopathy during systemic corticosteroid therapy. *Ophthalmology* 1995; **102**(5): 737–747.
- 5 Noltner WE, Rueckert PA. Elevated free cortisol index in pregnancy: possible regulatory mechanism. *Am J Obstet Gynecol* 1981; **139**(4): 492–498.
- 6 Williams Jr RB, Lane JD, Kuhn CM, Melosh W, White AD, Schanberg SM. Type A behaviour and elevated physiological and neuroendocrine responses to cognitive tasks. *Science* 1982; **218**(4571): 483–485.
- 7 Zmuda JM, Cauley JA, Kriska A, Glynn NW, Gutai JP, Kuller LH. Longitudinal relation between endogenous testosterone and cardiovascular disease risk factors in middle-aged men. A 13-year follow-up of former Multiple Risk Factor Intervention Trial participants. *Am J Epidemiol* 1997; **146**(8): 609–617.
- 8 Zumoff B, Rosenfeld RS, Friedman M, Byers SO, Rosenman RH, Hellman L. Elevated daytime urinary excretion of testosterone glucuronide in men with the type A behavior pattern. *Psychosom Med* 1984; **46**(3): 223–225.
- 9 Laudat MH, Guilhaume B, Blot P, Fournier C, Giaque JP, Luton JP. The hormonal state of pregnancy: modification of cortisol and testosterone. *Ann Endocrinol (Paris)* 1987; **48**(4): 334–338.
- 10 Rocha EM, Wickham LA, da Silveira LA, Krenzer KL, Yu FS, Toda I *et al.* Identification of androgen receptor protein and 5 alpha-reductase mRNA in human ocular tissues. *Br J Ophthalmol* 2000; **84**(1): 76–84.

MA Ahad<sup>1</sup>, CN Chua<sup>2</sup> and NM Evans<sup>1</sup>

<sup>1</sup>Royal Eye Infirmary, Plymouth, UK

<sup>2</sup>Oxford Eye Hospital, Oxford, UK

Correspondence: MA Ahad,  
Department of Clinical Ophthalmology,  
Moorfields Eye Hospital, London EC1V 2PD  
Tel: +44 0 20 7566 2266;  
Fax: +44 0 20 7251 9350.  
E-mail: ali71ahad@yahoo.com

*Eye* (2006) **20**, 503–505. doi:10.1038/sj.eye.6701905;  
published online 22 April 2005

Sir,  
**Spontaneous closure of Nd:YAG posterior capsulotomy  
in capsular blockage syndrome**

We report the spontaneous closure of a posterior capsule 1 week following Nd:YAG central posterior capsulotomy for capsular blockage syndrome, which developed following routine cataract surgery.

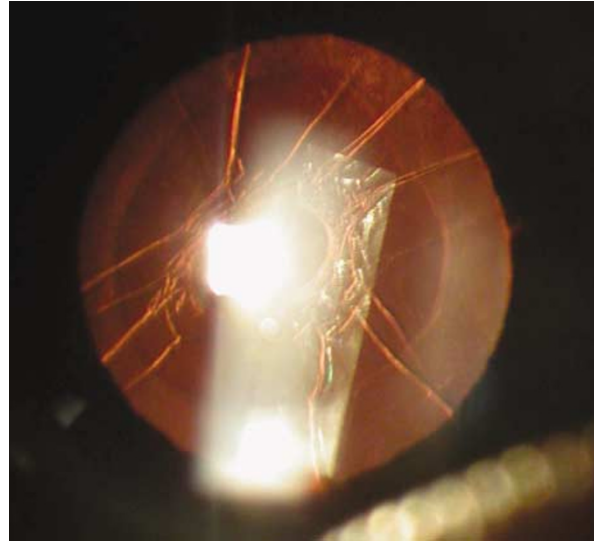
**Case report**

A 68-year-old nondiabetic, highly myopic man (with no other risk factors) underwent uncomplicated phacoemulsification cataract surgery. An MA50BM (Alcon Ft Worth TX) three-piece acrylic lens was implanted into the capsular bag. Postoperatively, capsular blockage syndrome type 2 was diagnosed.<sup>1</sup> A small central Nd:Yag posterior capsulotomy was performed to allow the escape of fluid.

After 1 week later, the posterior capsule opening was found to have closed with recurrence of capsular blockage syndrome. A larger Nd:YAG posterior capsulotomy was created, and the opening confirmed at 1 week. The outcome capsular bag had deflated and the anterior chamber deepened, with posterior movement of the optic, which had become adherent to the posterior capsule. This outcome has not been described as a part of conventional management of capsular blockage syndrome. The opening was patent at 3 months (Figure 1) and fibrosis noted around the opening, with migration of lens epithelial cells.

**Discussion**

Capsular blockage syndrome is well described, and occurs when viscoelastic is trapped between the lens and the posterior capsule. Intraoperative capsule blockage syndrome is type 1 and postoperative capsule blockage syndrome may be early (type 2, within 1 month) or late (type 3).<sup>1,2</sup>



**Figure 1** Photograph of lens capsule at 3 months after the capsulotomy.

Masket first reported closure of a posterior capsulotomy with Elschnig pearls along its margin, thought to be due to excessive lens epithelial cell (LEC) proliferation.<sup>3</sup> Kato *et al*<sup>4</sup> reported string of pearls in 47.6% of patients within 1 year after Nd:YAG posterior capsulotomy, but found no increased rate in high myopes. Kurosaka *et al*<sup>5</sup> report a 77% rate of Elschnig pearls at 2 years after Nd:YAG posterior capsulotomy, 20% requiring repeat laser. McPherson *et al*<sup>6</sup> report a 0.7% incidence of re-opacification after Nd:YAG capsulotomy. All affected patients were younger than 50 years at the time of cataract surgery. De Groot *et al*<sup>7</sup> showed that LECs can proliferate on the basal lamina of the anterior vitreous face and close a posterior capsulotomy. Chatterjee *et al*<sup>8</sup> reported capsule re-opacification 8 months after Nd:YAG capsulotomy of a 48-year-old diabetic gentleman following routine phacoemulsification and posterior chamber intraocular single-piece polymethyl methacrylate lens implantation (requiring a repeat Nd:YAG capsulotomy). Oshika *et al*<sup>9</sup> reported the closure of a capsulotomy in the presence of a glistening with hydrophobic acrylic lens. Surgical capsulotomy closure has also been reported in eyes at risk (uveitic, young adults).<sup>10</sup>

We report spontaneous closure of a Nd:YAG posterior capsulotomy for capsular blockage syndrome 1 week post-surgery, requiring repeat capsulotomy. This may be due to phimosis, but more likely from LEC migration. Our case differs from routine posterior capsulotomy in timing and anatomy. Capsulotomy was performed early when LECs were still stimulated following surgery, and the capsule was not adherent to the optic. It is our experience of human lens capsule culture that LECs will